

ABSTRACT

Valvular thrombectomy or replacement of stuck valve by surgery has been the traditional therapy for prosthetic valve thrombosis¹. From 1980 we have an alternative medical therapy in the form of thrombolysis. Major disadvantage with this therapy is the high incidence of recurrent thrombosis during follows up (20%). Recurrent thrombosis also can be treated with repeat thrombolysis with a high success rate but however it is advisable to replace the valve as a better option². We are reporting two patients with mitral valve replacement who underwent successful thrombolysis six and three times respectively for repeated stuck valve episodes.

Latchumanadhas K
Ezhilan J
Viswanathan V
Ramkumar S R
Rajan S
Mullasari Ajit S

INTRODUCTION

Prosthetic valve thrombosis is a rare but fatal complication in valve replacement patients with an annual incidence of 0.2%. It is more common in the mitral position than in the aortic position. Prosthetic valve thrombosis presentation can be acute due to thrombosis (58%), sub acute due to thrombus plus pannus (40%) and chronic due to pannus (2%). It can present as congestive cardiac failure, pulmonary emboli, cardiogenic shock, thromboembolism or death³. Valvular thrombectomy or valve replacement by surgery has been the traditional method of treating, but it has a mortality ranging from 10-15% and is still more if patient is haemodynamically unstable⁴. From 1980 we have a alternative medical therapy in the form of thrombolysis. It has a very high success rate of 82%, prevents another surgery and is cost-effective. However it can cause complications like thromboembolism(12%), stroke (8-10%), major bleeding (5%), recurrent thrombi(20%) and death(6%). Recurrent thrombi should usually be referred for replacement of the valve however thrombolysis can be repeated with high success rates in situations where surgical treatment is not available or affordable. We are reporting two such patients for whom thrombolysis was repeated six and three times respectively, for repeated stuck valve.

Key words :
prosthetic valve thrombosis,
thrombolysis
stuck valve

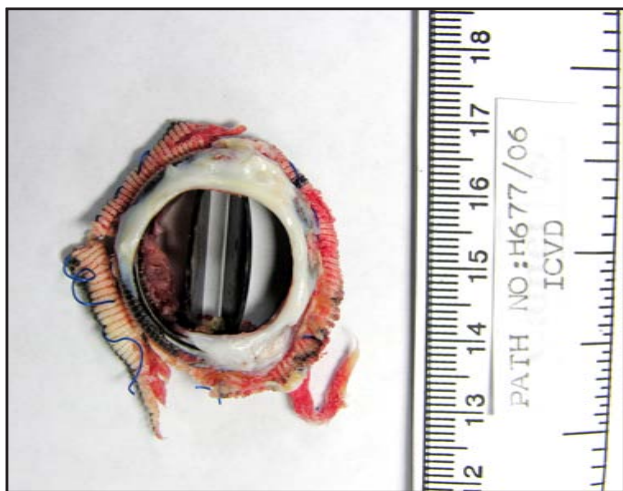CASE REPORT 1

A 56 years old woman with chronic rheumatic heart disease underwent Balloon Mitral Valvotomy for severe mitral stenosis in May 1994. She developed mitral restenosis with dense calcification and subvalvular fusion for which she underwent Mitral Valve Replacement (MVR) with 27mm Carbo Medics Bi-leaflet valve (Carbo Medics, Austin Tx) on 18-12-98. One year two months later she presented with acute breathlessness of 2 hours duration. Echocardiogram revealed a stuck mitral valve with peak gradient of 42 mm Hg, mean gradient of 34 mm Hg and mitral valve orifice area of 0.7cm². She was haemodynamically stable and was advised redo MVR. Coming from a poor socioeconomic status, financial constraints inhibited them from going for a redo MVR. Hence the option of thrombolysis was given. She underwent thrombolysis with streptokinase 250 000 U bolus in 30 minutes followed by 100 000 U/hour infusion. After 10 hours echocardiogram showed

*Department of Cardiology and Cardio
Vascular Surgery,
Institute of Cardio Vascular Disease,
Madras Medical Mission, Chennai*

complete resolution of thrombus and the peak and mean gradient had fallen to 14 and 8 mm Hg respectively with a mitral valve orifice area of 1.5cm². Streptokinase was discontinued and the patient was discharged after two days with instructions to strictly maintain her INR between 3-3.5 and monitor it every two months. In spite of regular follow up and maintaining her INR around three she returned three years later in March 2003 with repeat stuck valve. Again surgical option was refused on financial grounds and patient was thrombolysed successfully with streptokinase for the second time. Seven months later in October 2003 she was rehospitalized with stuck valve for the third time. This time since she had received streptokinase within a year, urokinase 4400 IU/kg over 30 minutes followed by 4400 IU/kg hourly infusion for 23 hours was given. The clot was lysed and mitral valve area increased from 0.5 cm² to 1.5 cm².

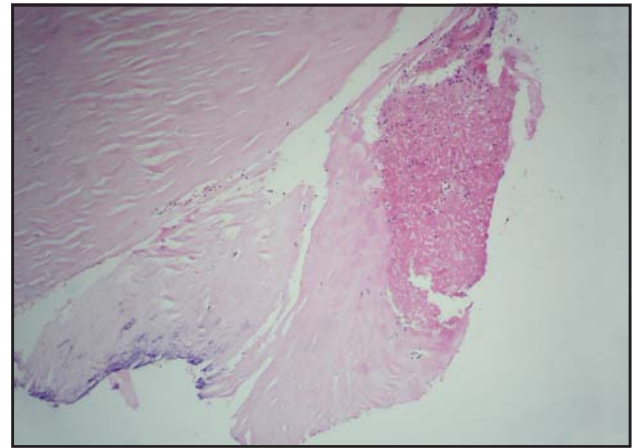
Figure 1: Explanted Prosthetic valve which got Stuck 6 times showing thrombus at 8 O' clock position



This time fluoroscopy for detecting fracture struts and blood investigations to rule out hypercoagulable state were done and were negative. Subsequently patient got readmitted on August 2004, November 2005 and November 2006 with the fourth, fifth and sixth episode of stuck valve and all the three times she was successfully thrombolysed with streptokinase. With financial aids from philanthropists, redo MVR with 25mm SJM Biocor valve was done on 14.12.06. The patient had an uneventful recovery and is doing well. The explanted prosthetic valve showed thrombus at 8 O' clock position. Histopathological examination of the

thrombotic material confirmed underlying pannus with thrombus deposition over it.

Figure 2: Light microscopic appearance with hematoxylin and Eosin stain showing underlying pannus with thrombus over it



CASE REPORT 2

A 56-year-old lady who underwent mitral valve replacement with 25mm TTK Chitra valve on 01-03-02 for chronic rheumatic heart disease with severe mitral regurgitation and moderate mitral stenosis, presented 17 months later with acute breathlessness. Echocardiography revealed prosthetic valve thrombosis with loss of leaflet mobility and high gradients across mitral valve. As the patient did not have the finances to undergo redo mitral valve replacement, patient was thrombolysed with standard dose of streptokinase. After 12 hours of infusion the thrombus was lysed and the gradients returned to basal levels. After increasing her oral anticoagulants and reaching target level of anticoagulation, patient was discharged. In spite of being on regular anticoagulation with target INR achieved, seven months later, she was admitted with a second episode of stuck valve in March 2004. Redo mitral valve replacement was advised but patients was not willing. As patient had received streptokinase within a year urokinase in the same standard dose as used for pulmonary embolism was given. The valve opened successfully to achieve basal gradients and valve orifice area. Fluoroscopy did not reveal any structural defect in the prosthesis and investigations for hypercoagulable state were normal. Seven months later patient developed ischaemic stroke involving left upper and lower limbs due to right internal capsular infarct. Patient was

managed medically and recovered with near normal power in the affected limbs. A year after the stroke she came back with third episode of stuck valve. This time in view of the stroke patient was strongly recommended redo MVR. But the patient could not arrange finances needed for a redo surgery forcing us to give the option of thrombolysis and she was willing to take the risk of stroke or major bleed. Patient was thrombolysed for the third time with streptokinase. The thrombolysis was successful and the transmitral gradients and valve orifice area returned to basal levels within 13 hours. She was discharged with oral anticoagulants to reach target INR, and has been advised elective redo mitral valve replacement.

DISCUSSION

Reoperation for repeated stuck valve is a more definitive treatment, with complete and thorough removal of thrombotic material. It also gives an opportunity to visualize the prosthetic valve for identification of valve related factors like structural defects or pannus formation, that may predispose to recurrent thrombosis⁵. As an alternative mode of therapy Luliago et al first described fibrinolysis in 1971. Since then a wide variety of fibrinolytic agents like streptokinase (250 000 IU bolus over 30 minutes followed by 100 000 IU/hr infusion) urokinase (4400 IU/kg over 30 minutes followed by 4400 IU/kg hourly infusion) and r-tPA (100 mg over 2-5 hours) have been used successfully^{6,7}. Thrombolysis with streptokinase and urokinase can be given for 24 hours after which it should be stopped and surgery can be performed 24 hours later or after 2 hours if protease inhibitors have neutralized fibrinolytic therapy. At any cost fibrinolytics must be discontinued after a maximum of 72 hours if not successful. Fibrinolysis results in complete successful thrombolysis in 76% of patients, and partial success was seen in another 10%. The remaining had failed thrombolysis. Major disadvantage with thrombolysis is a 20% incidence of recurrent thrombosis compared to 8% after thrombectomy and 3% after valve replacement⁸. Recurrent thrombosis may again be treated with thrombolysis with a success rate of 82%. However to limit the risk of complications recurring with each application of the thrombolytic agent and the increased probability of prosthetic valve dysfunction or pannus

growth, valve replacement is favored over repeated thrombolysis⁹. In developing countries and centers where surgical treatment is not available or if the patient is not affordable multiple thrombolysis can be given successfully and safely for recurrent stuck valves as a bailout option.

REFERENCES

1. Witchitz S, Veyrat, Moisson P, Scheinman N, Rozenstagen L. Fibrinolytic treatment of thrombus on prosthetic heart valves. *Br Heart J* 1980; 44:545-54
2. D.Hering, C.Piper, D Horstkotte. Management of prosthetic valve thrombosis. *Eur Heart J. Supplement* 2001; 3: (Suppl Q): Q-22 – 26
3. Roudaut R, Labbe T, Lorient-Roudaut MF et al. Mechanical cardiac valve thrombosis - is fibrinolysis justified ? *Circulation* 1992;86 (Suppl II) : 8 – 15
4. Vitile N, Renzulli A, Cerasulo F et al. Prosthetic valve obstruction : Thrombolysis versus operation. *Ann Thorac Surg* 1994; 57:365-70
5. Kontos GJ, Schaff HV, Orszulak TA, Puga FJ, Pluth JR, Danielson GK. Thrombotic obstruction of disc valves : Clinical recognition and surgical management. *Ann Thorac Surg* 1989;48:60-5
6. Lengyel M, Fuster V, Keltai M et al. Guidelines for management of left sided prosthetic valve thrombosis ; Role for thrombolytic therapy. *J Am Coll Cardiol* 1997 ; 30:1521 – 6
7. Bonow RO, Carabello B, DeLeon AC et al. ACC / AHA guidelines for the management of patients with valvular heart disease. A report of the American college of cardiology / American heart association task force on practice guidelines (committee on management of patients with valvular heart disease). *J Am Coll Cardiol* 1998;32:1486-588
8. Marcelo Kartz, Flavio Tarasoutchi, Max Grinberg. Thrombolytic therapy in prosthetic valve thrombosis. *Aquivos Brasileiros DE, Cardiologia* 2005; 85, 1
9. Gupta D, Kothari SS, Bahl VK, et al. Thrombolytic therapy for prosthetic valve thrombosis ; short and long term results. *Am Heart J* 2000;140:906-16